26 Eosinophil-Associated Dermatoses

Brendon Verhave and Lisa A. Beck

Chapter Contents

Eosinophil Biology 470
Tissue Effects and Innate Immunity 473
Eosinophil-Associated Dermatoses 473
Hypereosinophilic Syndromes 476

Key features

- Infiltration of eosinophils into the skin is not uncommon; therefore, clinicopathologic correlation is important to arrive at the correct clinical diagnosis
- Eosinophil-associated dermatoses include arthropod bite reactions and drug eruptions ("bugs and drugs"), atopic dermatitis, Wells syndrome, hypereosinophilic syndromes, autoimmune blistering diseases, and parasitic infections
- Activated eosinophils lose their morphologic integrity as they deposit toxic granule proteins and other inflammatory mediators in tissues; the absence of intact eosinophils may not be an accurate reflection of their relevance to a disease state
- In patients with persistent peripheral blood eosinophilia, as observed with hypereosinophilic syndromes, tissue infiltration and eosinophil-derived mediators may cause significant end-organ damage

EOSINOPHIL BIOLOGY

The eosinophil is a leukocyte ~10–16 microns in diameter that possesses a segmented (usually bi-lobed) nucleus. It is produced in the bone marrow and circulates transiently (8–18 hours) in the peripheral blood. Under normal conditions, circulating eosinophil counts range from 0 to 500 cells/mcl of human blood. Except for the bone marrow, gastrointestinal tract (distal to the esophagus), and lymphoid tissues (spleen, thymus, and lymph nodes), eosinophils are limited to diseased tissues.

In 1879, Paul Ehrlich named the "eosinophil" because of the intense staining of its distinctive cytoplasmic granules with the acidic dye, eosin. Ultrastructurally, eosinophils are characterized by membrane-bound, cytoplasmic granules that have an electron-dense core and less dense matrix (Fig. 26.1). The eosinophil produces multiple factors that make it a highly proinflammatory and pro-fibrotic leukocyte[1–3]. It also expresses a number of receptors on its cell surface that are important for activation[4,5], prolonged survival, and targeted migration into tissue compartments (see Fig. 26.1)[1–4,6].

Eosinophils are attracted into tissues by the coordinated actions of: (1) eosinophil activating cytokines (commonly referred to as "priming" cytokines); (2) tissue-released chemokines; and (3) endothelial adhesion molecules[7]. Eosinophils express receptors for granulocyte–macrophage colony-stimulating factor (GM-CSF), interleukin (IL)-3, and IL-5 which are important for bone marrow production, maturation, activation, and prolonged survival[1,3,8]. Several lines of investigation indicate that eosinophils are recruited to and activated within tissues by cytokines that largely come from a type 2 immune response (IL-33) or from Th2 cells (IL-4, IL-5, and IL-13). Natural killer cells also produce IL-5, and mast cell-derived cytokines contribute indirectly to eosinophil activation via induction of IL-5 and GM-CSF.

Eosinophils themselves elaborate important inflammatory and regulatory cytokines, including IL-1α, TGF-α and TGF-β_1, GM-CSF, IL-3, IL-5, IL-6, IL-8, TNF, and macrophage inflammatory protein 1α (CCL3; see Fig. 26.1). As a result, eosinophil activation also occurs in an autocrine manner. In cytotoxicity assays, eosinophils are maximally activated by GM-CSF, followed by IL-3, IL-5, TNF and IL-4, in order of potency[3,8]. Eosinophil numbers in the circulation and tissues is a function of balance of mediators that prolong survival versus those that induce apoptosis, like glucocorticoids. Glucocorticoids can counteract the prolonged survival induced by IL-3, IL-5 and GM-CSF, which may in part explain their therapeutic efficacy in most eosinophil-driven conditions. More recently, the surface receptors sialic acid-binding immunoglobulin-like lectins (Siglec) -8 and -10, which are expressed on eosinophils and mast cells, have been shown to mediate apoptosis[4].

Several members of the C-C chemokine gene superfamily are chemotactic for eosinophils, including the eotaxins 1, 2, and 3 (CCL11, CCL24, and CCL26). These chemokines signal primarily through C-C chemokine receptor (CCR)-3, which is highly expressed on eosinophils. In addition to their chemotactic properties, these chemokines also induce the release of reactive oxygen species. Eotaxins are produced by tissue resident cells positioning them as upstream mediators of cutaneous inflammation[9].

Eosinophils enter tissues by traversing blood vessels. Similar to other leukocytes, this transmigration involves adhering to endothelial adhesion molecules within the selectin and immunoglobulin supergene families[1,3]. In particular, eosinophils constitutively express very late antigen (VLA)-4, the ligand for vascular cell adhesion molecule (VCAM)-1; the latter is a cytokine-inducible endothelial adhesion molecule (see Fig. 102.11). After entering tissues, eosinophil activity is influenced by interactions between integrins on the eosinophil cell surface and both extracellular proteins (fibronectin, laminin, or collagen) and glycosaminoglycans (hyaluronic acid or chondroitin sulfate), which are induced under inflammatory conditions.

Granular Contents

Upon activation, eosinophils release their granular contents into the extracellular spaces by three mechanisms[1]: cytolytic degranulation, piecemeal degranulation, and regulated secretion. Cytolytic degranulation is characterized by organelle rupture, chromatolysis of nuclei with loss of morphologic integrity, and extensive deposition of eosinophil granules and granule products within tissue[1,3]; this process occurs in many inflammatory disorders, including atopic dermatitis, as well as in affected organs (including the skin) in patients with hypereosinophilic syndromes (HES).

Eosinophil major basic protein 1 (eMBP1), the constituent of the granules' crystalline cores (see Fig. 26.1), directly damages helminths and mammalian cells, exemplified by its ability to cause exfoliation of bronchial epithelial cells. In addition, eMBP1, but none of the other eosinophil granule proteins, induces basophil histamine release. Furthermore, eMBP1 stimulates neutrophils, leading to the release of superoxides and lysozyme. *Eosinophil cationic protein* (ECP or RNase3) and *eosinophil-derived neurotoxin* (EDN or RNase2) are members of the RNase family. ECP is a potent toxin for parasites through a different mechanism than eMBP1 and is more effective at killing certain helminths than eMBP1. EDN, as its name implies, is a neurotoxin and also has antiviral activity against RNA viruses.

Eosinophil peroxidase (EPO) kills numerous microorganisms in the presence of hydrogen peroxide (generated by eosinophils and other phagocytes) and halides. This combination of products also initiates mast cell secretion. Binding of EPO to microbes, including *Staphylococcus aureus*, greatly potentiates their killing by phagocytes. Similarly, EPO-coated tumor cells are spontaneously lysed by activated macrophages, and eMBP1 is also toxic to tumor cells. EPO and eMBP1 are potent platelet agonists that lead to release of 5-hydroxytryptamine (serotonin) and promote clotting.

In summary, the highly basic granule proteins released by activated eosinophils have evolved to not only protect us from parasitic helminths but also some bacteria and viruses, and they may in some settings possess anti-tumor properties.

Downloaded for Anonymous User (n/a) at Egyptian Knowledge Bank from ClinicalKey.com by Elsevier on March 10, 2024. For personal use only. No other uses without permission. Copyright ©2024. Elsevier Inc. All rights reserved.

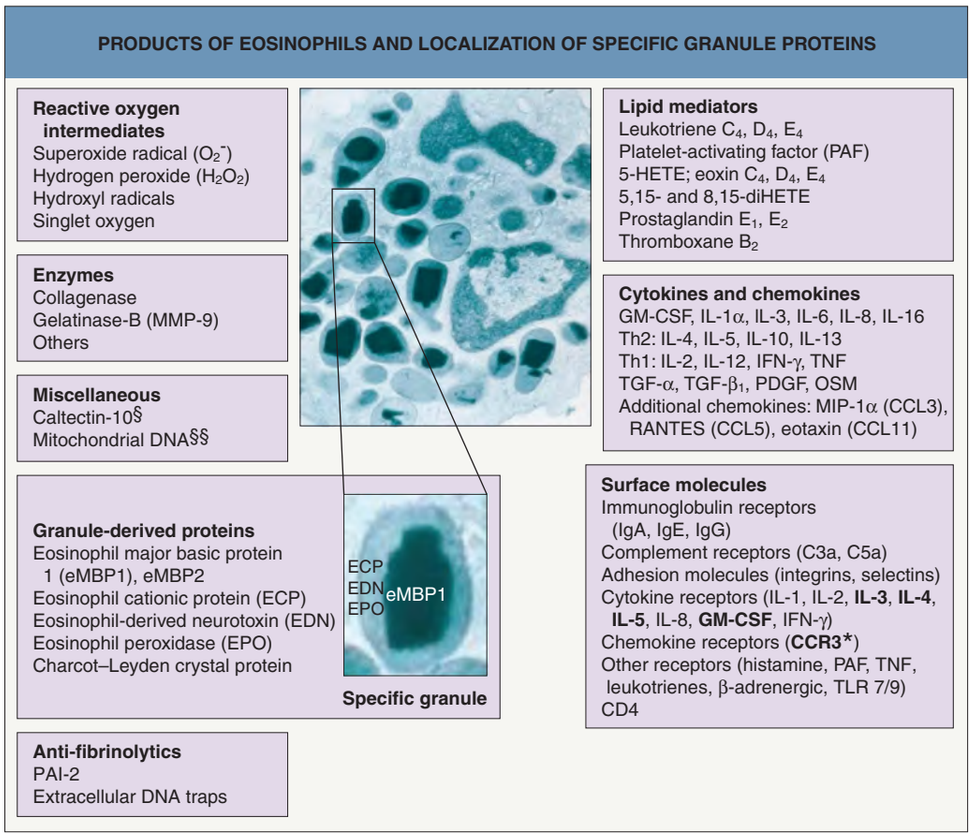

Fig. 26.1 Products of eosinophils and localization of specific granule proteins. The eosinophil produces myriad products that determine its role in inflammation. Specific granules contain major basic protein 1 and 2 (in the electron-dense core) and other toxic proteins (in the matrix). *Receptor for eotaxins and RANTES. §Charcot–Leyden crystal protein. §§Forms mitochondrial DNA traps with ECP and eMBP1. CCL, chemokine ligand; CCR, CC chemokine receptor; GM-CSF, granulocyte–macrophage colony-stimulating factor; HETE, *h*ydroxy*e*icosa*t*etra*e*noic acid; IFN, interferon; IL, interleukin; MIP, macrophage inflammatory protein; MMP, matrix metalloproteinase; OSM, oncostatin M; P2X4, P2X purinoceptor 4; PAI-2, plasminogen-activator inhibitor; PDGF, platelet-derived growth factor; RANTES, *r*egulated on *a*ctivation, *n*ormal *T* cell *e*xpressed and *s*ecreted; Siglec, sialic acid-binding immunoglobulin-type lectins; TGF, transforming growth factor; TLR, toll-like receptor; TNF, tumor necrosis factor.

EOSINOPHIL-ASSOCIATED DERMATOSES	
Diagnosis	**Clinical clues**
Common entities	
Allergic contact dermatitis (Ch. 14)	History of exposure; suggestive distribution; positive patch test
Arthropod bite/sting reactions (Ch. 85)	Primarily involves exposed skin; mosquitoes, fleas, spiders, ticks, and mites; exaggerated reactions in patients with CLL
Atopic dermatitis (Ch. 12)	History of atopy; pruritus; flexural accentuation; lichenification
Drug eruptions (Ch. 21)	Drug history, especially new drugs within the previous 2 weeks or up to 6 weeks for DRESS/DIHS Histopathologically, eosinophils are present in ~50% of cutaneous drug reactions
Erythema toxicum neonatorum (Ch. 34)	Newborn with erythematous macules, papules and pustules, often with prominent erythematous flare
Parasitic infections, particularly helminths (Ch. 83)	Cysticercosis, dirofilariasis, larva migrans, gnathostomiasis, onchocerciasis, schistosomiasis, and others
Scabies (Ch. 84)	Marked nocturnal pruritus; web-space, umbilical and groin involvement; close physical contact
Urticaria (Ch. 18)	Pruritic, migratory, transient wheals; individual lesions last <24 hours
Less common entities	
Annular erythema of infancy[58] (Ch. 19)	Annular or serpiginous non-pruritic plaques in infants
Autoimmune bullous dermatoses (Chs. 29–32; see Table 29.4 for differential diagnosis of eosinophilic spongiosis)	Pemphigoid (particularly bullous pemphigoid, gestational pemphigoid) > pemphigus, linear IgA bullous dermatosis, dermatitis herpetiformis, epidermolysis bullosa acquisita
Eosinophilic dermatosis associated with hematological disorders (eosinophilic dermatosis of hematologic malignancy; Ch. 33)	Most common in patients with CLL, but reported in patients with other hematologic malignancies; severe insect bite reactions as well as insect bite-like reactions
Eosinophilic fasciitis (Shulman syndrome; Ch. 43)	Acute onset of symmetrical induration of skin and subcutaneous tissues of the limbs; peripheral blood eosinophilia
Eosinophilic granulomatosis with polyangiitis (EGPA; Ch. 24)	Palpable purpura and tender papulonodules; peripheral blood eosinophilia; pulmonary (e.g. asthma), neurologic (e.g. mononeuritis multiplex), and cardiac involvement; prominent IgG4 and IgE responses

Table 26.1 Eosinophil-associated dermatoses.

Downloaded for Anonymous User (n/a) at Egyptian Knowledge Bank from ClinicalKey.com by Elsevier on March 10, 2024. For personal use only. No other uses without permission. Copyright ©2024. Elsevier Inc. All rights reserved.

EOSINOPHIL-ASSOCIATED DERMATOSES	
Diagnosis	**Clinical clues**
Eosinophilic (pustular) folliculitis (Ch. 38)	*Immunosuppression, including HIV infection and post-transplant**:* severe pruritus and papules on the face and upper trunk
	Ofuji disease: chronic, recurrent follicular pustules in a seborrheic distribution with a tendency to form circinate plaques; most commonly observed in east Asia
	Pediatric: follicular pustules on the scalp of an infant
Eosinophilic, polymorphic, and pruritic eruption associated with radiotherapy (EPPER)[59]	Local and generalized pruritus; erythematous papules and sometimes vesicles
Eosinophilic vasculitis (histopathologic reaction pattern rather than specific dermatosis)[60]	Pruritic urticarial and purpuric papules, angioedema; juvenile temporal arteritis (see below)
Eosinophilic ulcer of the oral mucosa (Ch. 72)	Rapidly enlarging nodule that develops ulceration; tongue most common site
Epithelioid hemangioma (angiolymphoid hyperplasia with eosinophilia; Ch. 114)	Single or multiple nodules of the face, scalp, and/or ears
Granuloma faciale (Ch. 24)	Red-brown plaque(s), often with prominent follicular openings; lesions favor the face
Hypereosinophilic syndromes (HESs)	See text
Incontinentia pigmenti (Ch. 62)	Vesicles and bullae along the lines of Blaschko in neonate (stage I); peripheral blood eosinophilia
Juvenile temporal arteritis	Nodule in the temporal region in an older child or young adult due to eosinophilic vasculitis
Juvenile xanthogranuloma (Ch. 91)	Yellow to red–brown papules or nodules on the head and neck, upper trunk or proximal extremities; early lesions may have numerous eosinophils
Kimura disease (Ch. 114)	Subcutaneous masses and lymphadenopathy of the head and neck region; peripheral blood eosinophilia, increased serum IgE levels
Langerhans cell histiocytosis (especially eosinophilic granuloma; Ch. 91)	Disseminated pink and yellow–brown papules (often with crusts); intertriginous involvement; occasionally, nodules
Lymphoproliferative disorders of the skin, benign and malignant (Chs. 119–121)	Presentation varies depending upon specific type; variable number of eosinophils seen in entire spectrum of lymphoproliferative disorders and commonly observed in LyP and cutaneous ALCL
Cutaneous mastocytosis (Ch. 118)	Pink–tan to red–brown macules, papules and plaques that urticate with stroking (Darier sign)
Papuloerythroderma of Ofuji (see Ch. 10)	Most commonly in elderly men; widespread, pruritic, red–brown papules that may become more confluent with characteristic sparing of the skin folds ("deck-chair" sign); peripheral blood eosinophilia and elevated serum IgE level; can be associated with malignancies (especially CTCL), infections, or drugs
Polymorphic eruption of pregnancy (PEP; also referred to as pruritic urticarial papules and plaques of pregnancy [PUPPP]; Ch. 27)	Primigravida in third trimester; urticarial papules and plaques, especially in striae
Pruritic papular eruption of HIV disease[61] (Ch. 78)	Pruritic non-follicular papules in a symmetric distribution; HIV infection; may be an exaggerated reaction to arthropod antigens but without a recognized history of bites
Seabather's eruption (e.g. larvae of *Linuche unguiculata* and *Edwardsiella lineata*; Ch. 85)	Pruritic papules of skin covered by swimsuit; occurs after ocean swimming
Small vessel vasculitis (leukocytoclastic vasculitis; Ch. 24)	Palpable purpura that favors the lower extremities; eosinophils more commonly observed in drug-induced variant
Swimmer's itch or cercarial dermatitis (larvae of avian and mammalian schistosome species; Ch. 83)	Pruritic papules on uncovered skin; occurs after fresh-water swimming
Urticarial allergic eruption	Annular or gyrate urticarial plaques that persist >24 hours
Wells syndrome	See text
Less well-defined entities, with overlapping features	
Papular dermatitis (itchy red bump disease)	Markedly pruritic pink to red papules; may be associated with eczematous patches and/or dermographism; spongiotic dermatitis often seen histologically
Urticarial dermatitis	Very pruritic, urticarial and/or eczematous lesions involving the trunk and proximal extremities; favors the elderly (chronic eczematous eruption of aging) and may reflect immunosenescence; often requires UVB phototherapy, dapsone or systemic immunosuppressives (e.g. MTX, dupilumab) for control
Exudative discoid and lichenoid chronic dermatosis of Sulzberger and Garbe (oid-oid disease)[62]	Middle-aged men; pruritic lesions commonly involving genitals; progressive stages: discoid → exudative → lichenified; peripheral blood eosinophilia; possible variant of nummular dermatitis
Pachydermatous eosinophilic dermatitis[63]	South African Black teenage girls with generalized pruritic papules, hypertrophic genital lesions and peripheral blood eosinophilia; dapsone-responsive; possibly a variant of hypereosinophilic dermatitis of Nir–Westfried

*Hematopoietic stem cell or solid-organ.

Table 26.1 Eosinophil-associated dermatoses. *It should be emphasized that variable numbers of eosinophils may be encountered in a large number of inflammatory, neoplastic, and infectious skin disorders, in addition to those listed in this table.* ALCL, anaplastic large cell lymphoma; CLL, chronic lymphocytic leukemia; CTCL, cutaneous T cell lymphoma; DIHS, drug-induced hypersensitivity syndrome; DRESS, drug reaction with eosinophilia and systemic symptoms; LyP, lymphomatoid papulosis; MTX, methotrexate.

Downloaded for Anonymous User (n/a) at Egyptian Knowledge Bank from ClinicalKey.com by Elsevier on March 10, 2024. For personal use only. No other uses without permission. Copyright ©2024. Elsevier Inc. All rights reserved.

TISSUE EFFECTS AND INNATE IMMUNITY

The presence of eosinophils in healthy tissues such as the gastrointestinal tract suggests that they may also have a homeostatic function. In addition, eosinophil infiltration is associated with tissue remodeling and fibrosis. Although cytokines, including IL-5 and eotaxins, are known to mediate eosinophil development and survival, mechanisms underlying the basal regulation of eosinophils, including their circadian cycling, remained largely unknown until the identification of innate lymphoid cells (ILCs). Long-lived type 2 ILCs, also known as ILC2s, are resident in peripheral tissues and regulate basal eosinophilopoiesis and tissue eosinophil accumulation via constitutive and stimulated cytokine expression[10–12]. ILC2s secrete IL-5 constitutively and are induced to co-express IL-13 during type 2 inflammation, resulting in localized eotaxin production and eosinophil accumulation.

Studies of the interactions of skin ILCs with other cell types demonstrated that dermal ILCs interact selectively and strongly with mast cells[12,13]. Type 2 innate lymphocytes have been designated part of the "Th2 franchise", and a broad role for ILC2s is emerging for both eosinophils and metabolic homeostasis, e.g. in atopic dermatitis[10], in glucose metabolism within adipose tissue[14] and adipose tissue remodeling[15], and in allergic respiratory disease[16]. Interactions of eosinophils with nerves may in part explain pruritus and other neurophysiological changes (e.g. white dermographism) observed in eosinophil-infiltrated tissues[17,18].

Eosinophils may act as antigen-presenting cells for microbial (including staphylococcal superantigens), viral, and parasitic antigens, promoting T cell proliferation. They also play a role in the regulation of mast cell function. Activation of eosinophils via toll-like receptors (TLR) 7 and TLR9 affects several eosinophil functions, with the overall response influenced by a Th2-like cytokine milieu[19]. In addition, eosinophils can generate mitochondrial DNA traps that contain ECP and eMBP1 which have antimicrobial activity and can promote thrombosis. In summary, eosinophils participate in innate and acquired immunity[2] and their functional diversity has numerous ramifications for both homeostasis and disease pathogenesis[1].

EOSINOPHIL-ASSOCIATED DERMATOSES

"Eosinophil-associated dermatoses" encompass a wide range of diseases characterized by the presence of a few to many eosinophils and/or evidence of eosinophil degranulation in skin and/or mucous membranes. Disorders characteristically associated with eosinophil infiltration include arthropod bite reactions and ectoparasite infestations (see Chs. 84 & 85), drug eruptions (see Ch. 21), atopic dermatitis (see Ch. 12), helminth infections (see Ch. 83), and Wells syndrome (Fig. 26.2). However, there are a number of other skin diseases where tissue eosinophilia may be present, including bullous pemphigoid, urticaria, and eosinophilic granulomatosis with polyangiitis (EGPA; Churg–Strauss syndrome) (Table 26.1). In addition, tissue eosinophilia can be observed in a wide range of skin disorders, from inflammatory to infectious to neoplastic.

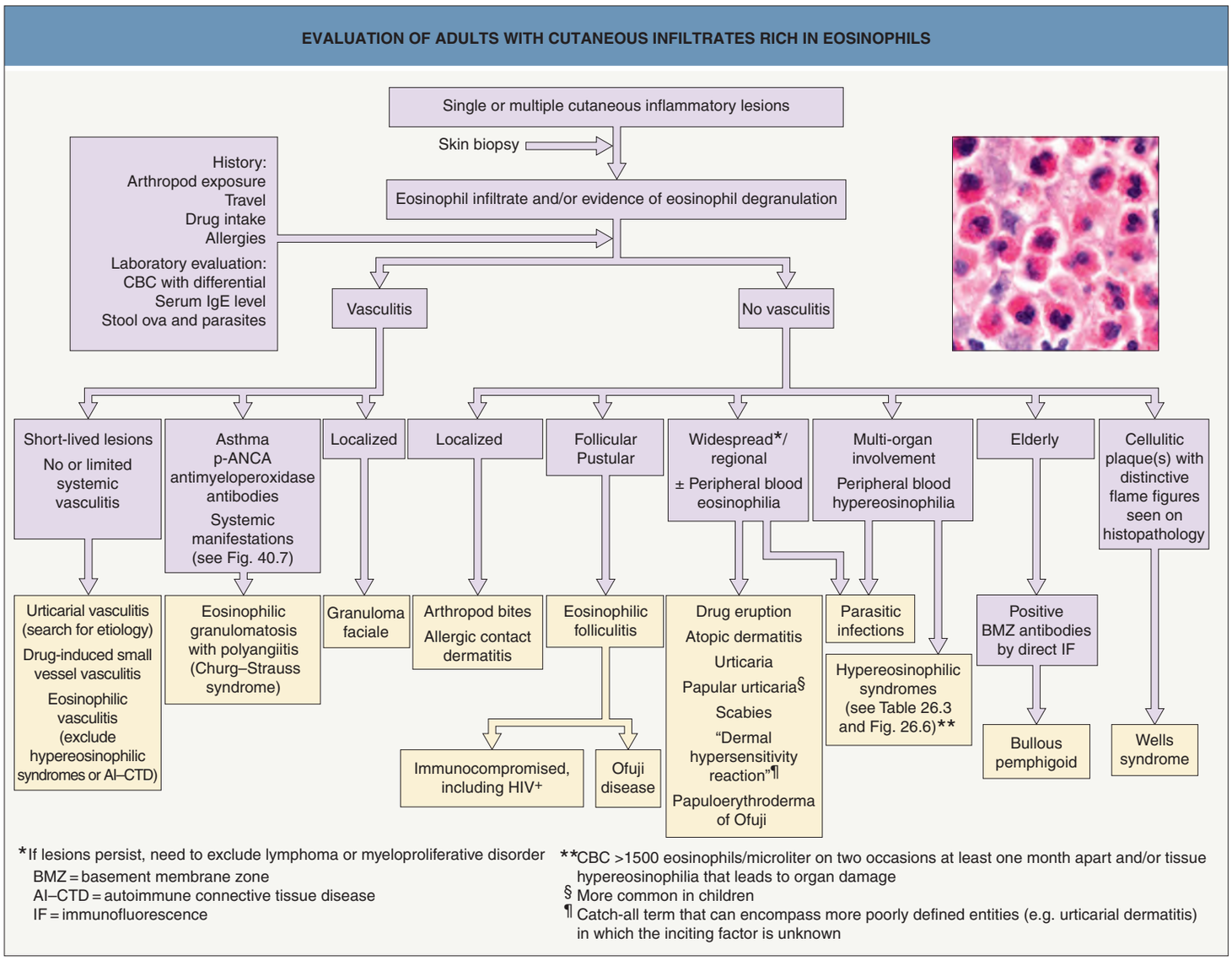

Fig. 26.2 Evaluation of adults with cutaneous infiltrates rich in eosinophils. These disorders are characterized histologically by eosinophil infiltration and/or eosinophil granule protein deposition. Peripheral blood eosinophilia occurs in some patients. Of note, systemic corticosteroids can significantly reduce the peripheral blood eosinophil count. *Photomicrograph, courtesy Lorenzo Cerroni, MD.*

Downloaded for Anonymous User (n/a) at Egyptian Knowledge Bank from ClinicalKey.com by Elsevier on March 10, 2024. For personal use only. No other uses without permission. Copyright ©2024. Elsevier Inc. All rights reserved.

More recently, it has been noted that mild to moderate peripheral eosinophilia (up to 35%–40%), along with tissue infiltration, is a key feature of IgG4-related disease (IgG4-RD[20]; Table 26.2)[20]. Initially described as a pancreatic disorder with increased serum IgG4 levels and numerous IgG4-positive plasma cells in affected tissues, the spectrum of IgG4-RD has been expanded to include any organ, including skin. Proposed cutaneous manifestations are granuloma faciale and lesions that resemble angiolymphoid hyperplasia with eosinophilia (see Table 26.2 & Ch. 24).

Wells Syndrome

Synonym: ▪ Eosinophilic cellulitis

Key features

- The characteristic presentation is recurrent, painful and/or pruritic, edematous to indurated plaques
- Histologically, a diffuse dermal infiltrate composed of eosinophils and histiocytes is seen as are foci of amorphous/granular material, termed "flame figures", which reflect localized degranulation of eosinophils
- Flame figures are a characteristic but are not diagnostic feature, as they can be observed in a wide range of eosinophil-rich dermatoses
- Distinction between Wells syndrome as a specific entity and a reaction pattern occurring in the setting of another dermatosis may be difficult
- Dramatic improvement after administration of systemic corticosteroids

Introduction

Wells syndrome is a cutaneous disorder of unknown etiology characterized by one or more edematous (early) to indurated (late) plaques that resemble well-demarcated cellulitis. The classic histopathologic findings consist of a diffuse dermal infiltrate of eosinophils plus characteristic "flame figures".

History

Wells described the first patient in 1971 as "recurrent granulomatous dermatitis with eosinophilia". He later renamed the disease "eosinophilic cellulitis"[21]. Spigel and Winkelmann[22] proposed the eponym, Wells syndrome, in 1979.

Epidemiology

Over 100 cases of Wells syndrome have been reported to date, ranging from newborns to patients over 70 years of age.

Pathogenesis

The pathogenesis of Wells syndrome is unknown. Local hypersensitivity due to "triggers" has been proposed, including insect bites or stings, drugs, allergic contact dermatitis, an underlying malignancy, and infections (e.g. dermatophytes, viruses, *Toxocara canis*)[23,24]. Of note, peripheral lymphocytes isolated from patients with Wells syndrome were reported to have exaggerated responses to mosquito salivary gland extracts[25]. Activated eosinophils clearly play a major role in the pathophysiology of Wells syndrome and it is thought that Th2 cells, and IL-5 in particular, are responsible for eosinophil recruitment and activation in this disease[26].

Clinical features

In Wells syndrome, there are recurrent episodes of prodromal itching or burning, accompanied by markedly edematous plaques. The latter may have an annular or arcuate configuration[27], and vesicles and bullae can also be seen. Initially, the lesions are bright red, and then they fade to a pink–brown or slate-gray color (Fig. 26.3). The plaques may become indurated, and lesions usually resolve over 4 to 8 weeks. Less common clinical presentations include papules and hemorrhagic bullae. The extremities are most frequently affected, but involvement of the trunk can also be seen. The most common systemic complaint is malaise, with fever in less than a quarter of patients. Peripheral blood eosinophilia is common. Patients are often misdiagnosed as having erysipelas or acute cellulitis. Precipitating events, including arthropod bites and stings or vaccinations, have been described in a minority of patients[28].

Pathology

An interstitial dermal infiltrate of eosinophils, admixed with lymphocytes and histiocytes is seen (Fig. 26.4). The infiltrate is most prominent in the mid to deep dermis, with occasional involvement of the subcutaneous fat, fascia, and skeletal muscle. The superficial dermis may have massive papillary dermal edema to the point of subepidermal bulla formation. Intraepidermal vesiculation, with eosinophilic spongiosis, may also be present.

IgG4-RELATED DISEASE (IgG4-RD) AND CUTANEOUS DISORDERS THAT MAY HAVE INCREASED LESIONAL IgG4$^+$ PLASMA CELLS	
Characteristic findings (not present in all patients)	

• Clinical: swelling or mass(es) in one or more organ(s)/tissue(s)
• Blood: increased serum IgG4 level; increased serum IgE level; eosinophilia or hypereosinophilia
• Histopathology of affected organ(s)/tissue(s):
  • Dense infiltrates of lymphocytes and plasma cells
  • Fibrosis (typically storiform pattern)
  • IgG4$^+$ to IgG$^+$ plasma cells >40%; >10 IgG4$^+$ plasma cells/hpf
  • Eosinophil infiltrates
  • Obliterative phlebitis	

Affected organs/tissues and/or manifestations – emerging spectrum	
• Pancreas (autoimmune pancreatitis)	• Sclerosing cholangitis
• Lacrimal glands (bilateral)	• Salivary glands (often submandibular; bilateral; Mikulicz disease)
• Retroperitoneal fibrosis (previously viewed as idiopathic)	• Sinonasal eosinophilic angiocentric fibrosis
• Thyroid (Riedel thyroiditis, fibrous variant of Hashimoto thyroiditis)	• Aorta (aortitis, periaortitis)
• Orbit (pseudotumor, proptosis)	• Lung, pleura, pericardium, kidney (tubulointerstitial nephritis), prostate, stomach (lymphoplasmacytic gastritis), breast (sclerosing mastitis, pseudotumor)
Cutaneous disorders that may have increased lesional IgG4$^+$ plasma cells	
• Granuloma faciale	• Angiolymphoid hyperplasia with eosinophilia
• Kimura disease	• Rosai–Dorfman disease
• Cutaneous plasmacytosis	

Table 26.2 IgG4-related disease (IgG4-RD) and cutaneous disorders that may have increased lesional IgG4$^+$ plasma cells[64,65]. Corticosteroids represent the first-line treatment for systemic involvement, with anti-CD20 or anti-CD19 antibodies, Bruton tyrosine kinase inhibitors, and anti-SLAMF7 antibodies as potential additional therapies. hpf, high power field.

Downloaded for Anonymous User (n/a) at Egyptian Knowledge Bank from ClinicalKey.com by Elsevier on March 10, 2024. For personal use only. No other uses without permission. Copyright ©2024. Elsevier Inc. All rights reserved.

In addition to intact eosinophils, extracellular eosinophil granules are present in the dermis. The characteristic brightly eosinophilic flame figures consist of collagen fibers coated with eosinophil granule proteins[29] (Fig. 26.4, inset). Utilizing indirect immunofluorescence assays, extracellular eMBP1 from eosinophil granules has been localized to flame figures[30]. In addition, a palisade of histiocytes and a few multinucleated giant cells partially surround these flame figures. While flame figures are considered a hallmark of Wells syndrome, they are not a specific finding[31]. Flame figures can also be seen in other disorders in which degranulation of eosinophils occurs including arthropod bite and sting reactions, scabies, and less often, parasitic infections (e.g. onchocerciasis), bullous pemphigoid, pemphigus vegetans, and EGPA.

Fig. 26.3 Wells syndrome – clinical features. A Large edematous, erythematous plaque on the leg surrounded by several smaller plaques and nodules. This presentation may be misdiagnosed clinically as infectious cellulitis. **B** More mature dull pink nodules and plaques. *A, Courtesy Luis Requena, MD.*

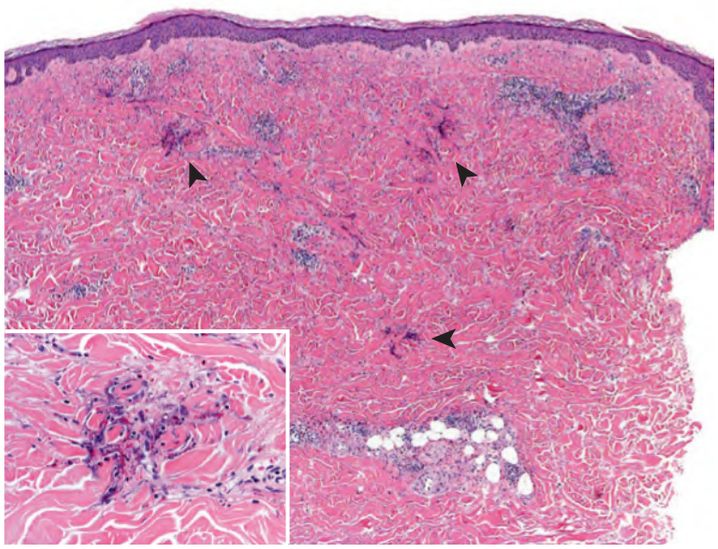

Fig. 26.4 Wells syndrome – histopathologic features. Perivascular and interstitial inflammatory infiltrates that contain eosinophils. There are several flame figures at sites of degranulated eosinophils (arrowheads; inset). *Courtesy Lorenzo Cerroni, MD.*

Differential diagnosis

Wells syndrome often has a striking clinicopathologic presentation[32]. Early on, bacterial cellulitis and erysipelas are the most common clinical mimics. The histopathologic findings of both erysipelas and bacterial cellulitis can also include significant edema, but neutrophils are the predominant inflammatory cell in these soft tissue infections. Other causes of pseudocellulitis, including exaggerated reactions to arthropod bites, should be considered (see Table 74.10).

Toxocara canis and other parasitic infections can present with clinical and pathologic findings resembling Wells syndrome. When a parasitic infection is suspected, laboratory evaluation including stool examinations, specific parasite serologies, and even PCR of stool may be necessary. Other disorders that may present with urticarial plaques due to infiltrates of eosinophils are listed in Table 26.1. Late (mature) lesions of Wells syndrome may clinically, but not histologically, resemble morphea.

Eosinophilic annular erythema (EAE) is also in the differential diagnosis, but this entity is considered by many to be a subset of Wells syndrome. EAE is a figurate erythema that presents with annular and polycyclic skin lesions due to dermal infiltrates of eosinophils. However, flame figures are uncommon. EAE has been observed in patients with a number of conditions including malignancy, autoimmune thyroid disease, borreliosis, chronic gastritis caused by *Helicobacter pylori* infection, diabetes mellitus, hepatitis C virus, chronic kidney disease, thymoma, and autoimmune pancreatitis[33].

Treatment

Initial therapy with prednisone 10–80 mg daily results in dramatic improvement within a few days in most patients[34]. Tapering the dose over one month is generally well tolerated. Flares or recurrence may be treated with additional courses of prednisone. Steroid-sparing medications, including minocycline, colchicine, antimalarials, dapsone,

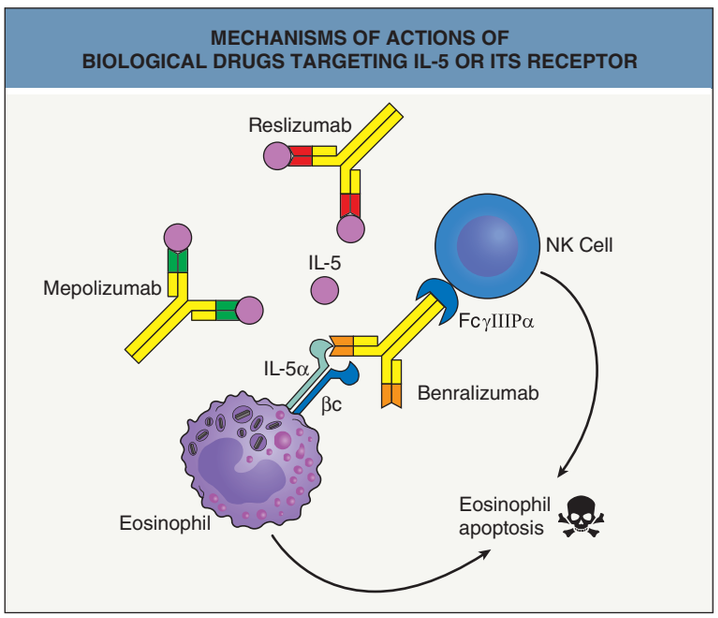

Fig. 26.5 Mechanisms of action of monoclonal antibodies that target IL-5 and IL-5Rα monoclonal antibodies. Anti-IL-5 antibodies inhibit its biological effects on eosinophils. Benralizumab interacts, via its Fab region, with the α subunit of the IL-5 receptor, thereby neutralizing IL-5 bioactivity. In addition, its Fc region binds to the FcγIIIRa on NK cells which induces apoptosis of eosinophils. See Ch. 138 for discussion of monoclonal antibodies that target the IL-4 receptor and IL-13. *From Pelaia C, Paolett G, Puggioni F, et al. Interlukin-5 in the pathophysiology of severe asthma. Front Physiol 2019;10:1514.*

Downloaded for Anonymous User (n/a) at Egyptian Knowledge Bank from ClinicalKey.com by Elsevier on March 10, 2024. For personal use only. No other uses without permission. Copyright ©2024. Elsevier Inc. All rights reserved.

griseofulvin, interferon-α and antihistamines, have limited evidence of efficacy. Recent reports suggest benefit with dupilumab, omalizumab (anti-IgE), mepolizumab (anti-IL-5), and benralizumab[35–37] (anti-α chain of IL-5R) (Fig. 26.5). For milder cases, potent topical corticosteroids may be sufficient[35–37].

HYPEREOSINOPHILIC SYNDROMES

Key features

- Mucocutaneous lesions occur in over 50% of patients with hypereosinophilic syndromes (HESs), most commonly presenting as pruritic erythematous papules or nodules, urticaria, angioedema, and/or mucosal ulcers
- Classification and treatment of HESs became more precise with discovery of the *FIP1L1-PDGFRA* fusion gene, whose protein product is a constitutively activated tyrosine kinase; additional chromosomal rearrangements have been identified that involve *PDGFRA*, *PDGFRB*, *FGFR1*, and *PCM1-JAK2* which encode platelet-derived growth factor receptor (PDGFR)-α, PDGFR-β, fibroblast growth factor receptor 1, and pericentriolar material 1/Janus kinase 2, respectively
- Based upon recently adopted terminology and classification criteria, primary (neoplastic) and secondary (reactive) forms of HES have been more clearly defined
- The *FIP1L1-PDGFRA* fusion gene and other genetic abnormalities (see above) are present in patients with primary (neoplastic) HES, which includes eosinophilic leukemia
- The lymphocytic (lymphoid) subtype of secondary (reactive) HES is characterized by a clonal proliferation of T cells with increased production of Th2 cytokines, particularly IL-5
- End-organ damage may occur from sustained tissue eosinophilia, including life-threatening endomyocardial fibrosis and/or thrombosis

Introduction

The term "hypereosinophilic syndrome" or "HES" was coined in the late 1960s to refer to a spectrum of eosinophil-associated diseases with common clinical features, including peripheral eosinophilia (>1500 cells/mcl) and internal organ involvement. In the 1990s, a subset of patients with HES was found to have a clonal proliferation of T cells, with increased production of IL-5. In 2003, it was discovered that some patients with the HES variant that responded to imatinib had a *FIP1L1-PDGFRA* fusion gene due to a chromosomal translocation[38]. Its protein product is a constitutively activated tyrosine kinase that is 100 times more sensitive to inhibition by imatinib than the BCR-ABL kinase present in chronic myelogenous leukemia (CML) patients. Since then, additional genetic abnormalities have been identified[8] and a number of HES variants have been described (Table 26.3)[39], leading to more tailored treatment recommendations (Fig. 26.6)[11,40].

History

The term "hypereosinophilic syndromes (HESs)" was first coined in 1968 with the diagnostic criteria initially proposed in 1975[41]. This was followed by the description of two major variants of HES – lymphocytic (LHES) and myeloproliferative (MHES). In 2011, experts from multiple disciplines came to a consensus regarding terminology and classification criteria during the Working Conference on Eosinophil Disorders and Syndromes[4,32,39]. The currently recognized clinical variants are outlined in Table 26.3[40]. Of note, the World Health Organization's definition of HES excludes myeloid variants associated with molecular abnormalities[42].

Epidemiology

Up to 25% of patients have associated HES (see Table 26.3), which has an equal sex distribution, while MHES (*FIP1L1-PDGFRA*- or other mutation-positive HES) has a striking male predominance (>90%). HES can affect all age groups, but the majority are adults. While individuals with the *FIP1L1-PDGFRA* fusion gene may be regarded as having chronic eosinophilic leukemia, there are rare patients who develop more aggressive disease with transformation to acute leukemia[8]. Patients with LHES are at risk for developing lymphoma.

Clinical Features

Patients present with signs and symptoms related to the organ systems affected by eosinophilic infiltrates. The most common mucocutaneous findings are pruritic erythematous macules, papules, plaques or nodules on the trunk and extremities or urticaria and angioedema[43,44]. Other cutaneous manifestations include erythema annulare centrifugum-like lesions, livedo reticularis, retiform purpura, and superficial thrombophlebitis, with the thrombotic entities occurring almost exclusively in primary HES.

Since eosinophils have been implicated as the primary cause of end-organ damage in all forms of HES, clinical improvement usually parallels a decrease in both blood and tissue eosinophilia[45]. However, the underlying pathogenesis of variants other than MHES and LHES still remains unclear[39]. Occasionally, patients with episodic angioedema with eosinophilia (Gleich syndrome) or the *n*odules, *e*osinophilia, *r*heumatism, *d*ermatitis and *s*welling (NERDS) syndrome may develop T cell clones and fulfill the diagnostic criteria for LHES (see Table 26.3). Therefore, as outlined in Figure 26.6, patients who cannot be classified as either MHES or LHES should continue to be monitored for cytogenetic abnormalities or T cell clonality[46,47].

Pathology

The histopathology of cutaneous lesions of HES is nonspecific and varies depending upon the type of skin lesion biopsied. Urticarial lesions have findings similar to ordinary urticaria, i.e. perivascular > interstitial infiltrates of lymphocytes, eosinophils, and occasional neutrophils. Biopsies from papules or plaques occasionally exhibit spongiosis in addition to the dermal infiltrate that usually contains at least a few eosinophils. Flame figures are occasionally present. When studied with immunohistochemical or immunofluorescence stains for specific eosinophil granule proteins, HES mucosal ulcers show extensive deposition of granule proteins in the absence of morphologically identifiable intact eosinophils. Thrombosis of dermal blood vessels has been observed in biopsy specimens from retiform purpura and necrotic skin lesions in HES patients.

Differential Diagnosis

The clinical and histopathologic differential diagnosis of HES includes other eosinophil-associated dermatoses (see Table 26.1), along with other dermatoses in which eosinophil degranulation occurs but infiltrates of intact eosinophils are not observed. The footprint of eosinophil participation is deposition of granular contents (e.g. eMBP1), which remain in the tissue while the cell itself is not morphologically identifiable, although parts of the eosinophil may be recognizable by electron microscopy. However, most other eosinophil-associated dermatoses will not be associated with peripheral blood hypereosinophilia of >1.5 cells × 10^9/L.

In contrast to Wells syndrome, patients with primary HES tend to be more systemically ill, with signs and symptoms of multi-organ involvement. Occasionally, dermal flame figures are seen in skin lesions of HES. EGPA can resemble HES clinically and is considered by some authors to be an HES-associated disease. Patients with EGPA have asthma as well as prominent IgG4 and IgE responses (see Ch. 24)[48]. While patients with EGPA have vasculitis of small and medium-sized vessels, vasculitis is an uncommon feature of HES. However, thromboembolic phenomena may produce lesions that mimic vasculitis (see Ch. 22).

Parasitic infections and infestations may closely resemble HES. A history of travel to endemic areas or a suggestive dietary history implicates helminthiasis. In such patients, serologic testing for anti-*Strongyloides* antibodies and three stool samples for ova and parasites should be obtained. A total serum IgE level >500 IU/ml is often seen in helminth infections. Inappropriate treatment of *Strongyloides stercoralis* with systemic corticosteroids or other immunosuppressives may result in severe sequelae, including death.

Downloaded for Anonymous User (n/a) at Egyptian Knowledge Bank from ClinicalKey.com by Elsevier on March 10, 2024. For personal use only. No other uses without permission. Copyright ©2024. Elsevier Inc. All rights reserved.

DIAGNOSTIC CRITERIA AND CLASSIFICATION OF HYPEREOSINOPHILIC SYNDROMES (HESs) AND OTHER ENTITIES WITH HYPEREOSINOPHILIA		
Three diagnostic criteria		
1. Peripheral blood hypereosinophilia – defined as >1.5 eosinophils × 10^9/L blood [>1500 eosinophils/mcl]* on two examinations at an interval of one month or greater† – and/or – Tissue hypereosinophilia defined by the following: • Percentage of eosinophils in bone marrow section exceeds 20% of all nucleated cells – and/or – • Pathologist is of the opinion that tissue infiltration by eosinophils is extensive – and/or – • Marked deposition of eosinophil granule proteins is found in the absence or presence of major tissue infiltration by eosinophils 2. Organ damage and/or dysfunction attributable to tissue hypereosinophilia 3. Exclusion of other disorders or conditions as major reason for organ damage		
Variants of HES (end-organ damage attributable to hypereosinophilia)		
Myeloid HES (MHES, neoplastic, primary) – 15%–20%	***Lymphocytic HES (LHES, secondary)***	***Overlap HES – eosinophilic disease restricted to a single organ – or – a defined eosinophilic syndrome that overlaps in clinical features with idiopathic HES***
• Underlying neoplasm of stem cells, myeloid cells, or eosinophils (WHO classification) • Eosinophils are considered (or shown) to be clonal‡ • Male predominance • In addition to typical skin lesions (see text), signs of cutaneous thromboses (e.g. retiform purpura) • Mucosal ulcers poor prognostic sign • Fever, weight loss, malaise, subendocardial fibrosis, restrictive cardiomyopathy, mitral or tricuspid valve insufficiency, hepatosplenomegaly, neutrophilia • Some patients have high serum tryptase and vitamin B_{12} levels, tissue fibrosis, splenomegaly, and bone marrow biopsies with increased numbers of $CD25^+$ atypical spindle-shaped mast cells¶	• Hypereosinophilia is thought to be cytokine-driven, due to clonal T cells§ producing Th2 cytokines (IL-5, -4, -13) • Skin is most commonly affected organ (severe pruritus, dermatitis, erythroderma, urticaria, angioedema) • Lymphadenopathy • Serum IgE and TARC (CCL17) levels are typically elevated (likely due to actions of IL-4, -13) • T cell clone often remains stable for years, but transformation to lymphoma can occur	• Episodic angioedema with eosinophilia (Gleich syndrome)‖ • Nodules, eosinophilia, rheumatism, dermatitis and swelling (NERDS) syndrome‖ • Eosinophilic granulomatosis with polyangiitis (EGPA) • Eosinophilia myalgia syndrome and toxic oil syndrome (both historic)
Associated HES (secondary, reactive)		***Overlap HES (eosinophilic disease restricted to an organ other than the skin)***
• HES in the setting of a known secondary cause • Hypereosinophilia cytokine-driven (IL-3, IL-5, GM-CSF), but not due to clonal T lymphocytes • Associated with underlying primary immunodeficiencies (e.g. Omenn syndrome, hyper IgE syndrome [*STAT3* or *DOCK8* mutations]), atopic diseases, helminth or other infections, drug hypersensitivity or other inflammatory disorders (e.g. chronic GVHD), hematologic or solid-organ malignancies • Systemic mastocytosis, including with an associated hematologic (non-mast cell lineage) neoplasm • Hypereosinophilia also seen in patients with cholesterol emboli, inflammatory bowel disease, and sarcoidosis		• Eosinophilic *gastrointestinal* diseases – eosinophilic esophagitis, gastroenteritis, colitis, pancreatitis, and hepatitis; eosinophilic ascites • Eosinophilic *pulmonary* diseases – eosinophilic asthma, bronchitis, pneumonia, pleuritis, rhinosinusitis (and nasal polyposis) • Eosinophilic *genitourinary* diseases – nephritis, cystitis, endometritis, myometritis • Other eosinophilic diseases – mastitis, myocarditis, synovitis, ocular disorders

*Eosinophilia is defined as 0.5–1.5 eosinophils × 10^9/L blood.
†In the case of evolving life-threatening end-organ damage, the diagnosis of HES can be made immediately to avoid delay in treatment.
‡*FIP1L1-PDGFRA* fusion gene (>80% of patients) and other rarer fusion genes or rearrangements involving *PDGFRB*, *FGFR1* or *PCM1-JAK2*, which encode platelet-derived growth factor receptor-β, fibroblast growth factor receptor-1, and pericentriolar material 1/Janus kinase 2, respectively; includes patients with eosinophilic leukemia, who may have other cytogenetic abnormalities. Point mutations in *JAK2* may also be seen.
¶In the WHO classification of mastocytosis, such patients (who have the *FIP1L1-PDGFRA* fusion gene) are designated as having systemic mastocytosis with associated clonal hematological non-mast cell-lineage disease (AHNMD).
§Some patients have phenotypically abnormal lymphocyte populations with unique surface phenotypes (e.g. $CD3^+CD4^-CD8^-$, $CD3^-CD4^+$).
‖May develop T cell clones.

Table 26.3 Diagnostic criteria and classification of hypereosinophilic syndromes (HESs) and other entities with hypereosinophilia. Two additional clinical variants are ***idiopathic*** and ***familial***[40]; the latter is rare and may have an autosomal dominant transmission pattern (with one case mapped to chromosome 5q where the IL-5 gene cluster resides) and it is sometimes asymptomatic[6]. *Data from references 52–55.*

In patients with HES and isolated urticarial plaques with or without angioedema, the differential diagnosis includes ordinary urticaria. In such patients, demonstration of internal organ involvement favors HES. In addition, HES with episodic angioedema may resemble hereditary or acquired angioedema clinically, but complement studies help to distinguish these entities (see Fig. 18.19). Furthermore, patients with hereditary angioedema often have a family history of the disease and rarely are their peripheral blood eosinophil counts as high as in HES.

Treatment

If patients do not present with life-threatening manifestations, high-dose corticosteroids (e.g. prednisone 1 mg/kg/day), if indicated, can be initiated after the evaluation is complete (see Fig. 26.6). Patients should be administered ivermectin if there has been exposure to *Strongyloides*.

If *FIP1L1-PDGFRA* or other genetic abnormalities involving *PDGFRA* or *PDGFRB* are present, imatinib therapy is warranted (see Fig. 26.6)[46,47]. As a tyrosine kinase inhibitor, imatinib prevents autophosphorylation of the fusion protein and phosphorylation of other substrates, resulting in termination of the signaling cascade that induces genes related to eosinophil proliferation and activation. Patients respond to varying doses of imatinib, depending upon an individual patient's sensitivity and ability of the given dosage to suppress the mutant clone. Imatinib doses ranging from 400 mg daily to 100 mg weekly or less have proven effective. However, maintenance therapy is required to avoid relapse. Because endomyocardial disease may worsen during the first several days of imatinib administration, serum levels of troponin and

Downloaded for Anonymous User (n/a) at Egyptian Knowledge Bank from ClinicalKey.com by Elsevier on March 10, 2024. For personal use only. No other uses without permission. Copyright ©2024. Elsevier Inc. All rights reserved.

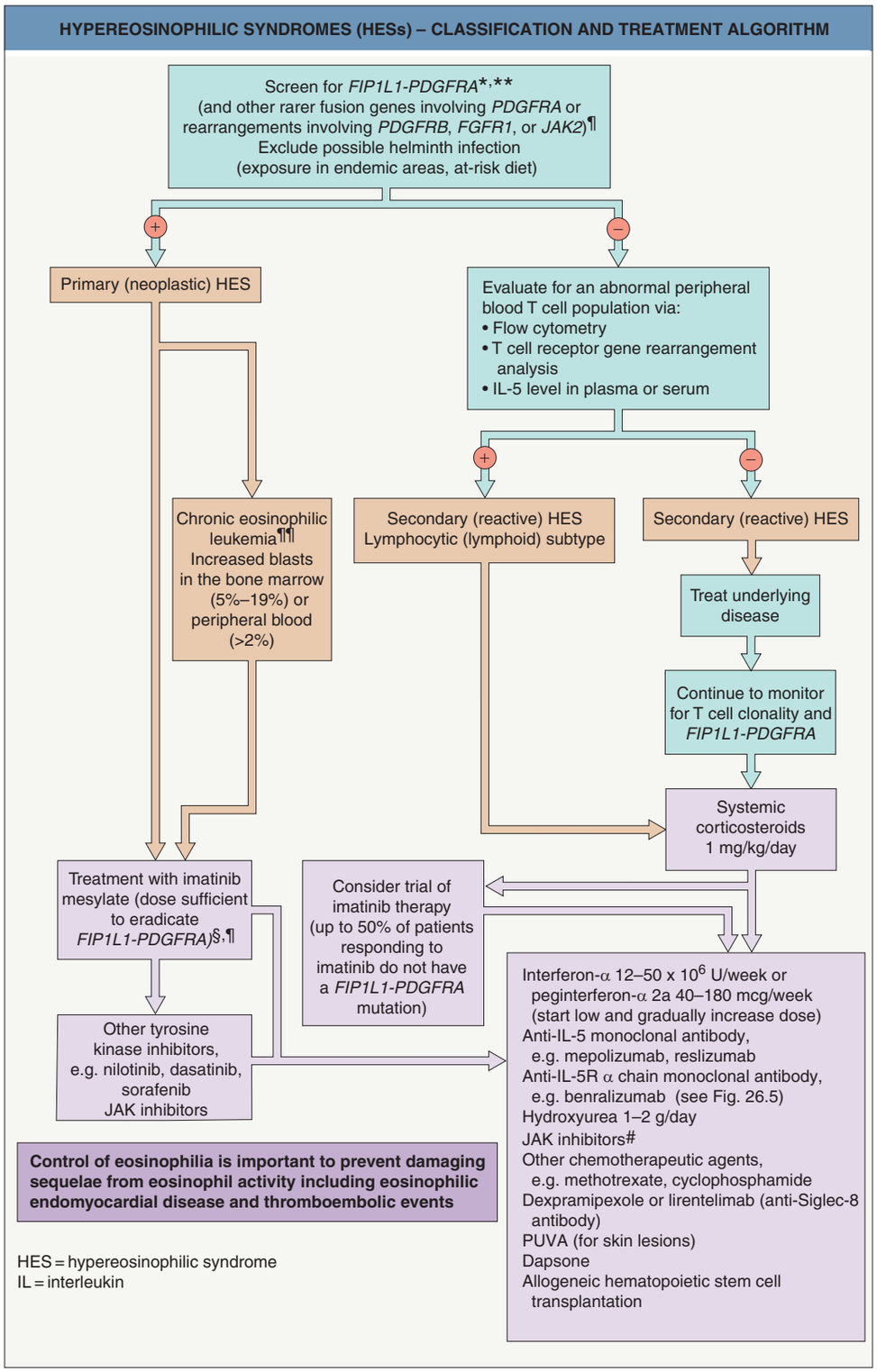

Fig. 26.6 Hypereosinophilic syndromes (HESs) – classification and treatment algorithm. *An 800 kb deletion on chromosome 4 produces a fusion gene composed of a portion of the *PDGFRA* (platelet-derived growth factor receptor α) gene that encodes its kinase domain linked to a previously uncharacterized gene that resembles *Fip1*, which encodes an essential component of the *Saccharomyces cerevisiae* polyadenylation machinery. The resultant product is a constitutively activated tyrosine kinase that is a target of the tyrosine kinase inhibitor, imatinib. Screening can be performed on a peripheral blood sample via reverse transcriptase-PCR or fluorescence *in situ* hybridization (FISH). **Bone marrow biopsy with cytogenetic studies should be done to exclude hematologic disorders that are accompanied by eosinophilia. Increased bone marrow mast cells and increased serum tryptase may be observed. ¶*PDGFRB*, *FGFR1*, and *JAK2* encode platelet-derived growth factor receptor-β, fibroblast growth factor receptor-1, and Janus kinase 2, respectively; patients with genetic abnormalities involving *PDGFRA* and *PDGFRB* typically respond to imatinib but not those involving *FGFR1*. Patients may become resistant due to new mutations (during blast crisis) or tandem mutations (during chronic phase). ¶¶May have other clonal cytogenetic and molecular genetic abnormalities; in the presence of eosinophilia, considered sufficient for diagnosis even in the absence of excess blasts. §Plus systemic corticosteroids if cardiac involvement. #Including those with *JAK2* mutations. *Data from refs 40,52–57.*

N-terminal pro-brain natriuretic peptide (NT-proBNP) should be monitored. Preemptive and concurrent treatment with corticosteroids is also recommended to maintain cardiac function. Other kinase inhibitors (nilotinib, dasatinib, and sorafenib) may also be useful in patients who do not respond to imatinib or become resistant as a consequence of mutations such as T674I in *FIP1L1-PDGFRA*[49].

Secondary HES is best managed by treating the underlying disease, once determined. When the underlying disease fails to respond to first-line therapies and the patient lacks *PDGFRA* or *PDGFRB* fusion genes, then corticosteroids are begun, usually prednisone at 1 mg/kg/day; ~70% of patients will respond, with the peripheral eosinophilia returning to normal levels. For patients who fail corticosteroid monotherapy or develop significant long-term side effects, there are several other therapeutic options (see Fig. 26.6). For example, patients with no detectable *FIP1L1-PDGFRA* fusion gene have achieved partial remission from imatinib, although the mechanism of response in these patients is unclear. Perhaps some patients had diagnostically occult *PDGFRA* or *PDGFRB* rearrangements[49]. Thus, imatinib represents a reasonable therapeutic option, given its relative safety.

Interferon (IFN)-α (12–50 × 10^6 U/week) has been beneficial in patients with both primary and secondary HES. Its mode of action is likely via myelosuppression but may include effects on Th2 helper cells by changing the cytokine milieu (including a decrease in IL-5 levels). For some patients, pegylated interferon (peginterferon-α 2a), administered weekly, is better tolerated. One concern regarding the use of IFN-α, based upon the findings of an *in vitro* study in which IFN-α acted as a growth factor for $CD3^-CD4^+$ cells, is probably minimized by concomitant corticosteroid therapy.

Downloaded for Anonymous User (n/a) at Egyptian Knowledge Bank from ClinicalKey.com by Elsevier on March 10, 2024. For personal use only. No other uses without permission. Copyright ©2024. Elsevier Inc. All rights reserved.

Two monoclonal antibodies against human IL-5 approved for the treatment of asthma, mepolizumab and reslizumab, and a monoclonal antibody directed against the alpha chain of the IL-5R, benralizumab, have been used to treat HES in clinical trials (see Fig. 26.5). Analyses of cytokine production by lymphocytes before and after treatment with mepolizumab showed a striking reduction in Th2 cytokine production (IL-13, IL-10) in addition to the expected IL-5 reduction[50]. In a randomized, double-blind, placebo-controlled trial involving *FIP1L1-PDGFRA*-negative patients who were already receiving prednisone (20–60 mg/day), administration of mepolizumab (750 mg IV every 4 weeks for 9 cycles) led to twice as many individuals (84% vs 43%) being successfully tapered to a stable prednisone dose of ≤10 mg/day[51].

The main treatment goals via single- or multiple-agent regimens are relief of symptoms and maintaining the peripheral eosinophil count in the range of $1–2 \times 10^9$/L blood or less[40]. HES patients also need to be routinely monitored for organ involvement, particularly cardiac disease, in addition to progression to lymphoma or leukemia. Patients who fail corticosteroid monotherapy have a worse prognosis.

Additional table on entities in which flame figures may be seen, available in our eBook (see inside front cover for access code).

ENTITIES IN WHICH FLAME FIGURES MAY BE SEEN
Angiolymphoid hyperplasia with eosinophilia
Arthropod bite and sting reactions
Autoimmune bullous diseases (e.g. pemphigoid, gestational pemphigoid, pemphigus vegetans)
Eosinophilic granulomatosis with polyangiitis (Churg–Strauss syndrome)
Eosinophilic pustular folliculitis
Hypereosinophilic syndromes
Incontinentia pigmenti
Kimura disease
Mastocytoma
Parasitic infections (e.g. ascariasis, onchocerciasis, gnathostomiasis, onchocerciasis, toxocariasis)
Wells syndrome

eTable 26.1 Entities in which flame figures may be seen.

Downloaded for Anonymous User (n/a) at Egyptian Knowledge Bank from ClinicalKey.com by Elsevier on March 10, 2024. For personal use only. No other uses without permission. Copyright ©2024. Elsevier Inc. All rights reserved.